

PATIENT

Simba Lamothe

SPECIES

Canine

BREED

Chow Chow

SEX

MN

AGE

11 y

WEIGHT

59.7 lb

INTERPRETED BY

Keith Blass, DVM, MS
DACVIM(Cardiology)

HOSPITAL NAME

Mass Veterinary Services

REFERRING VET

Dr. Masloski

INVOICE

DATE

12/16/21

PRESENTING CLINICAL SIGNS

Grade I-II/VI murmur. History of stage B2 degenerative valve disease and mild LV systolic dysfunction. Doing well. Receiving pimobendan 7.5 mg BID, enalapril 15 mg BID, taurine 1000 mg BID.

ECHOCARDIOGRAPHIC FINDINGS

2D, M-mode, and Doppler study.

Left atrial size is normal. The mitral valve leaflets are mildly thickened, and a mild jet of mitral regurgitation is present. There is mild left ventricular dilation. Left ventricular systolic function measures at the lower limit of normal. The aorta and aortic are normal. Right atrial and right ventricular dimensions are normal. The tricuspid valve is normal. The pulmonary artery and pulmonic valve are normal. No heartworms are visualized. No pericardial effusion or cardiac masses are seen.

LA - 41.1 mm
 LVIDd - 45.5 mm
 LVIDs - 33.8 mm
 FS - 25.6%
 RA - 29.3 mm
 LVOT - 1.68 m/s
 RVOT - 0.76 m/s

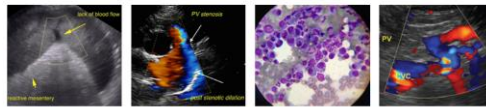
INTERPRETATION OF THE FINDINGS & FURTHER RECOMMENDATIONS

Degenerative mitral valve disease

This examination demonstrates slight improvement compared to Simba's previous echocardiogram, as he now has low-normal left ventricular systolic function and his left atrial size is normal. Given this, Simba's current risk for the development of clinical signs of cardiac dysfunction, such as coughing, exercise intolerance, syncope, and labored breathing, appears to be relatively low.

No change in therapy is recommended based on this exam.

A recheck echocardiogram is recommended in 6-9 months, sooner if new clinical signs compatible with cardiac dysfunction develop.



PATIENT

Simba Lamothe

SPECIES

Canine

BREED

Chow Chow

SEX

MN

AGE

11 y

WEIGHT

59.7 lb

INTERPRETED BY

Keith Blass, DVM, MS
 DACVIM(Cardiology)

Keith Blass, DVM, MS, DACVIM (Cardiology)

KeithBlass@gmail.com

631-804-5754

HOSPITAL NAME

Mass Veterinary
 Services

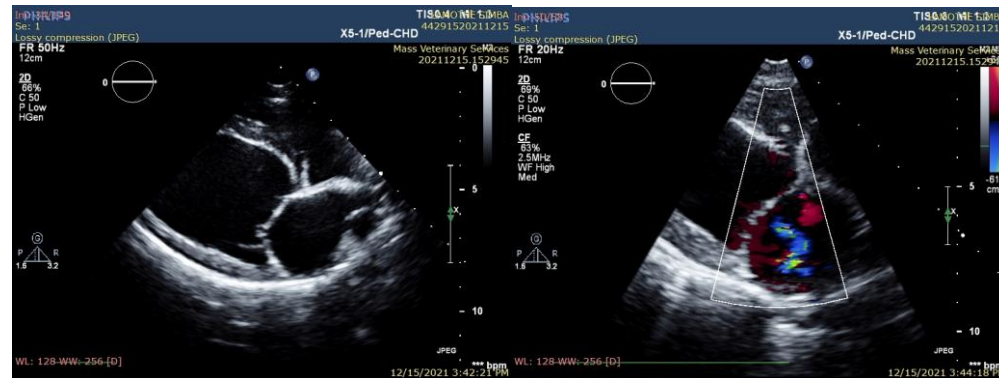
REFERRING VET

Dr. Masloski

INVOICE

DATE

12/16/21



The information and recommendations provided are based on the images presented by the referring veterinarian. No evaluation can be communicated regarding pathology that was not visible in the image/video clips provided.

Thank you for this referral. If the clinical or image interpretation does not parallel your findings or if I can be of any further assistance please contact me.